15 The Cranial Nerves and Trigeminal Nerve Blocks

Chapter Outline

CLINICAL TESTING OF THE CRANIAL NERVES

Systematic examination of the 12 cranial nerves is an important part of the examination of every neurologic patient. It may reveal a lesion of a cranial nerve nucleus or its central connections, or it may show an interruption of the lower motor neurons.

The letter symbols commonly used to indicate the functional components of each cranial nerve are shown in text Table 15-1. The different components of the cranial nerves, their functions, and the openings in the skull through which the nerves leave the cranial cavity are summarized in text Table 15-2.

Testing the Integrity of the Olfactory Nerve

The olfactory nerve can be tested by applying substances with different odors to each nostril in turn. It should be remembered that food flavors depend on the sense of smell and not on the sense of taste. Fractures of the anterior cranial fossa or cerebral tumors of the frontal lobes may produce lesions of the olfactory nerves, with consequent loss of the sense of smell (anosmia).

Testing the Integrity of the Optic Nerve

The optic nerve is evaluated by first asking the patient whether any changes in eyesight have been noted. The acuity of vision is then tested by using charts with lines of print of varying size. The retinas and optic discs should then be examined with an ophthalmoscope. When examining the optic disc, it should be remembered that the intracranial subarachnoid space extends forward around the optic nerve to the back of the eyeball. The retinal artery and vein run in the optic nerve and cross the subarachnoid space of the nerve sheath a short distance behind the eyeball. A rise in cerebrospinal fluid pressure in the subarachnoid space will compress the thin walls of the retinal vein as it crosses the space, resulting in congestion of the retinal veins, edema of the retina, and bulging of the optic disc (papilledema).

The visual fields should then be tested. The patient is asked to gaze straight ahead at a fixed object with the eye being tested, with the opposite eye covered. A small object is then moved in an arc around the periphery of the field of vision, and the patient is asked whether he or she can see the object. It is important not to miss loss or impairment of vision in the central area of the field (central scotoma).

Blindness in one half of each visual field is called hemianopia. Lesions of the optic tract and optic radiation produce the same hemianopia for both eyes, that is, homonymous hemianopia. Bitemporal hemianopia is a loss of the lateral halves of the fields of vision of both eyes (i.e., loss of function of the medial half of both retinas). This condition is most commonly produced by a tumor of the pituitary gland exerting pressure on the optic chiasma.

Testing the Integrity of the Oculomotor, Trochlear, and Abducent Nerves

The oculomotor, trochlear, and abducent nerves innervate the muscles that move the eyeball. The oculomotor nerve supplies all the orbital muscles except the superior oblique and the lateral rectus. It also supplies the levator palpebrae superioris and the smooth muscles concerned with accommodation—namely, the sphincter pupillae and the ciliary muscle. The trochlear nerve supplies the superior oblique muscle, and the abducent nerve supplies the lateral rectus.

To examine the ocular muscles, the patient's head is fixed and he or she is asked to move the eyes in turn to the left, to the right, upward, and downward, as far as possible in each direction.

In complete third-nerve paralysis the eye cannot be moved upward, downward, or inward. At rest the eye looks laterally (external strabismus) because of the activity of the lateral rectus and downward because of the activity of the superior oblique. The patient sees double (diplopia). Drooping of the upper eyelid (ptosis) occurs because of paralysis of the levator palpebrae superioris. The pupil is widely dilated and nonreactive to light because of the paralysis of the sphincter pupillae and the unopposed action of the dilator pupillae (supplied by the sympathetic). Accommodation of the eye is paralyzed.

In fourth-nerve paralysis the patient complains of double vision on looking straight downward. This is because the superior oblique is paralyzed and the eye turns medially as the inferior rectus pulls the eye downward.

In sixth-nerve paralysis the patient cannot turn the eyeball laterally. When looking straight ahead, the lateral rectus is paralyzed, and the unopposed medial rectus pulls the eyeball medially, causing internal strabismus.

Testing the Integrity of the Trigeminal Nerve

The trigeminal nerve has sensory and motor roots. The sensory root passes to the trigeminal ganglion, from which

emerge the ophthalmic (V1), maxillary (V2), and mandibular (V3) divisions. The motor root joins the mandibular division.

The sensory function can be tested by using a cotton wisp over each area of the face supplied by the divisions of the trigeminal nerve (CD Fig. 15-1).

The motor function can be tested by asking the patient to clench the teeth. The masseter and the temporalis muscles, which are innervated by the mandibular division of the trigeminal nerve, can be palpated and felt to harden as they contract.

Testing the Integrity of the Facial Nerve

The facial nerve supplies the muscles of facial expression; supplies the anterior two thirds of the tongue with taste fibers; and is secretomotor to the lacrimal, submandibular, and sublingual glands.

The anatomic relationship of this nerve to other structures enables a physician to localize lesions of the nerve accurately. If the sixth and seventh nerves are not functioning, this would suggest a lesion within the pons of the brain. If the eighth and seventh nerves are not functioning, this would suggest a lesion in the internal acoustic meatus. If the patient is excessively sensitive to sound in one ear, the lesion probably involves the nerve to the stapedius. Loss of taste over the anterior two thirds of the tongue implies that the seventh nerve is damaged proximal to the point where it gives off the chorda tympani.

To test the facial nerve, the patient is asked to show the teeth by separating the lips with the teeth clenched, and then to close the eyes. Taste on each half of the anterior two thirds of the tongue can be tested with sugar, salt, vinegar, and quinine for the sweet, salty, sour, and bitter sensations, respectively.

It should be remembered that the part of the facial nerve nucleus that controls the muscles of the upper part of the face receives corticobulbar fibers from both cerebral

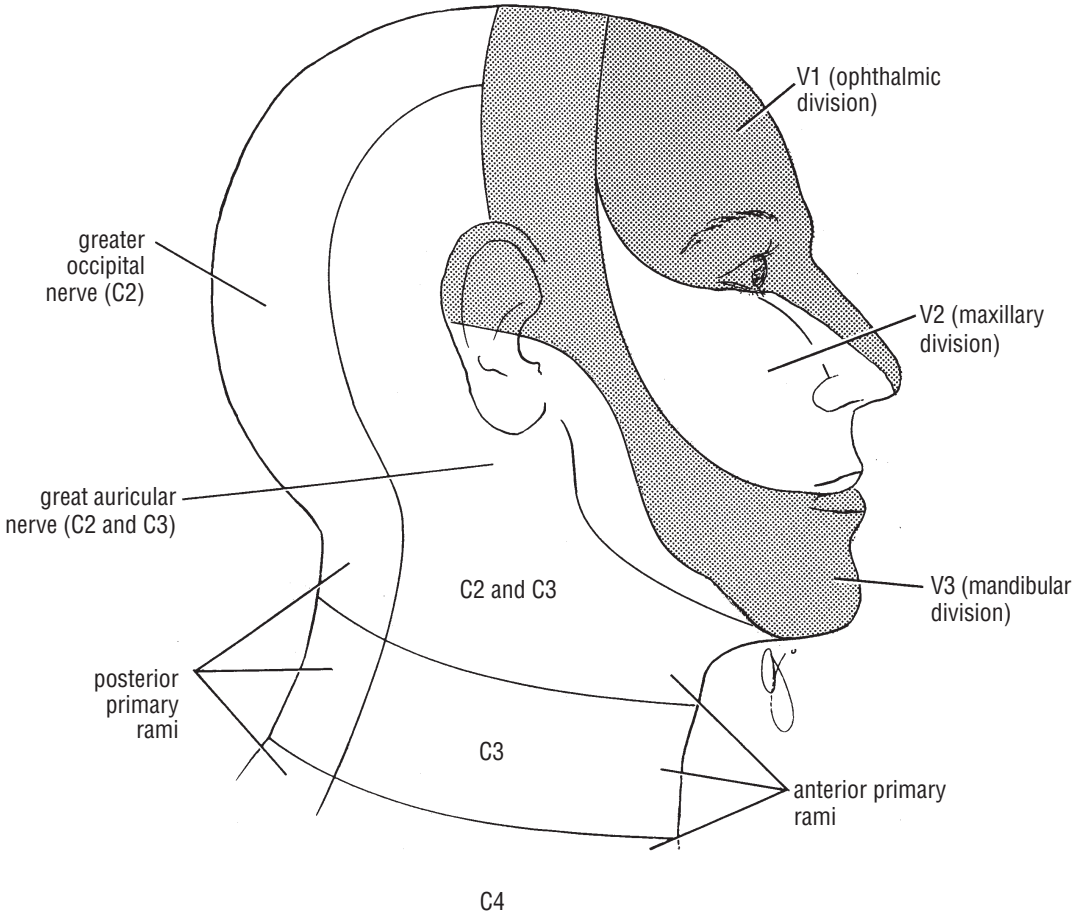

CD Figure 15-1 The facial cutaneous distribution of the ophthalmic (V1), maxillary (V2), and mandibular (V3) divisions of the trigeminal nerve. Note that the skin over the angle of the jaw is supplied by the great auricular nerve (C2 and C3 segments of the spinal cord).

cortices. Therefore, in patients with an upper motor neuron lesion, only the muscles of the lower part of the face will be paralyzed. However, in patients with a lower motor neuron lesion, all the muscles on the affected side of the face will be paralyzed. The lower eyelid will droop, and the angle of the mouth will sag. Tears will flow over the lower eyelid, and saliva will dribble from the corner of the mouth. The patient will be unable to close the eye and cannot expose the teeth fully on the affected side.

Testing the Integrity of the Vestibulocochlear Nerve

The vestibulocochlear nerve innervates the utricle and saccule, which are sensitive to static changes in equilibrium; the semicircular canals, which are sensitive to changes in dynamic equilibrium; and the cochlea, which is sensitive to sound.

Disturbances of vestibular function include dizziness (vertigo) and nystagmus. The latter is an uncontrollable pendular movement of the eyes. Disturbances of cochlear function reveal themselves as deafness and ringing in the ears (tinnitus). The patient's ability to hear a voice or a tuning fork should be tested, with each ear tested separately.

Testing the Integrity of the Glossopharyngeal Nerve

The glossopharyngeal nerve supplies the stylopharyngeus muscle and sends secretomotor fibers to the parotid gland. Sensory fibers innervate the posterior one third of the tongue.

The integrity of this nerve may be evaluated by testing the patient's general sensation and that of taste on the posterior third of the tongue.

Testing the Integrity of the Vagus Nerve

The vagus nerve innervates many important organs, but the examination of this nerve depends on testing the function of the branches to the pharynx, soft palate, and larynx. The pharyngeal reflex may be tested by touching the lateral wall of the pharynx with a spatula. This should immediately cause the patient to gag—that is, the pharyngeal muscles will contract.

The innervation of the soft palate can be tested by asking the patient to say "ah." Normally, the soft palate rises and the uvula moves backward in the midline.

All the muscles of the larynx are supplied by the recurrent laryngeal branch of the vagus, except the cricothyroid muscle, which is supplied by the external laryngeal branch of the superior laryngeal branch of the vagus. Hoarseness or absence of the voice may occur. Laryngoscopic examination may reveal abductor paralysis.

Testing the Integrity of the Accessory Nerve

The accessory nerve supplies the sternocleidomastoid and the trapezius muscles by means of its spinal part. The patient should be asked to rotate the head to one side against resistance, causing the sternocleidomastoid of the opposite side to come into action. Then the patient should be asked to shrug the shoulders, causing the trapezius muscles to come into action.

Testing the Integrity of the Hypoglossal Nerve

The hypoglossal nerve supplies the muscles of the tongue. The patient is asked to put out the tongue, and if a lesion of the nerve is present, it will be noted that the tongue deviates toward the paralyzed side (CD Fig. 15-2). This can be explained as follows. One of the genioglossus muscles, which pull the tongue forward, is paralyzed on the affected side. The other, normal genioglossus muscle pulls the unaffected side of the tongue forward, leaving the paralyzed side of the tongue stationary. The result is the tip of the tongue's deviation toward the paralyzed side. In patients with long-standing paralysis, the muscles on the affected side are wasted, and the tongue is wrinkled on that side.

CLINICAL ANATOMY OF TRIGEMINAL NERVE BLOCKS

Ophthalmic Nerve Block

The terminal branches of the ophthalmic division of the trigeminal nerve that emerge onto the face and nose include the supraorbital, supratrochlear, infratrochlear, external nasal, and lacrimal nerves (CD Fig. 15-3). The latter nerve gives off only a few branches to the skin and is seldom blocked.

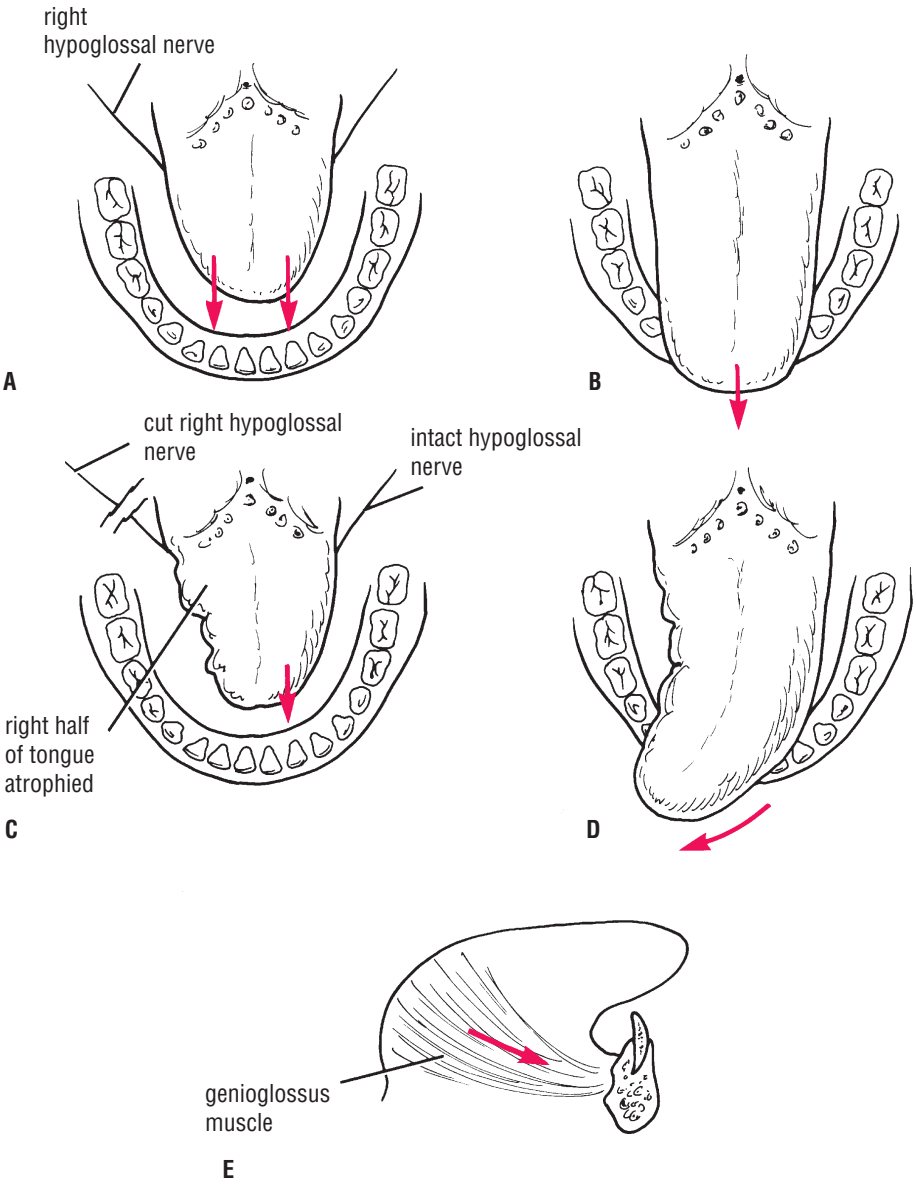

CD Figure 15-2 Diagrammatic representation of the action of the right and left genioglossus muscles of the tongue. **A.** The right and left muscles contract equally together and as a result (**B**) the tip of the tongue is protruded in the midline. **C.** The right hypoglossal nerve (which innervates the genioglossus muscle and the intrinsic tongue muscles on the same side) is cut and as a result the right side of the tongue is atrophied and wrinkled. **D.** When the patient is asked to protrude the tongue, the tip points to the side of the nerve lesion. **E.** The origin and insertion and direction of pull of the genioglossus muscle.

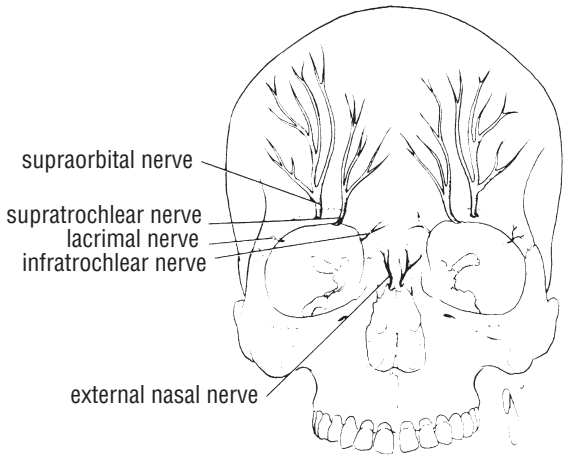

CD Figure 15-3 Anterior view of the skull showing the branches of the ophthalmic (V1) division of the trigeminal nerve emerging onto the face.

Supraorbital Nerve Block

This involves the following:

Area of Anesthesia

Skin of the upper eyelid, the forehead, and the scalp as far back as the vertex (CD Fig. 15-4)

Indications

Repair of lacerations of the upper eyelid, forehead, and scalp

Procedure

The supraorbital nerve emerges from the orbital cavity in the same vertical plane as the pupil when the patient is looking straight ahead (see CD Fig. 15-4). If the nerve passes through the supraorbital notch, this can easily be palpated on the

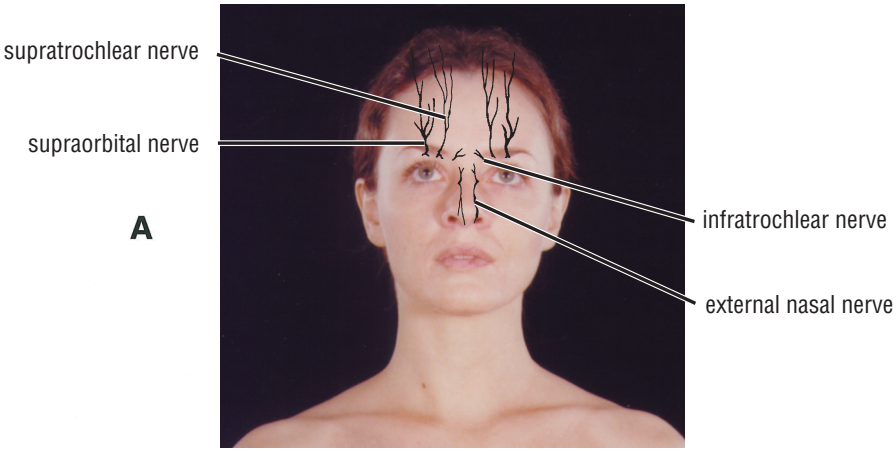

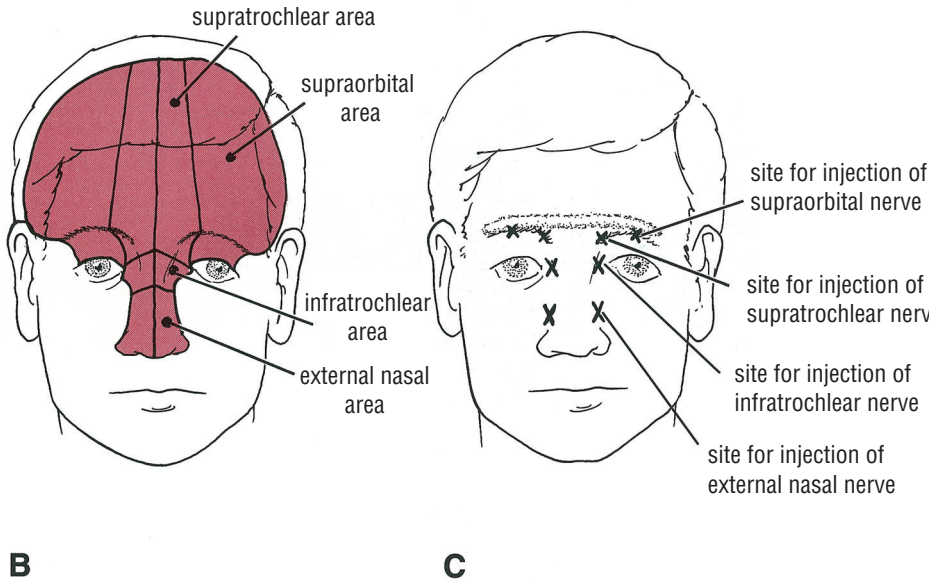

CD Figure 15-4 Supraorbital, supratrochlear, infratrochlear, and external nasal nerve blocks. **A.** The positions of the nerves on the face; the supraorbital nerve emerging from the orbital cavity in the same vertical plane as the pupil. **B.** The areas of skin anesthetized by blocking these nerves. **C.** Sites where the nerves may be blocked. The supraorbital and supratrochlear nerves may be blocked by raising a horizontal wheal of anesthetic solution above the orbital margin.

supraorbital margin, which is the site for injection. If the notch is a foramen, however, it is small and difficult to feel, and the needle is inserted into the skin over the supraorbital margin in line with the pupil.

Supratrochlear Nerve Block

This involves the following:

Area of Anesthesia

Skin of the upper eyelid and the lower forehead close to the midline (see CD Fig. 15-4)

Indications

Repair of lacerations of the medial end of the eyelid and the forehead close to the midline

Procedure

The supratrochlear nerve winds around the supraorbital margin about a fingerbreadth medial to the supraorbital nerve. The needle is inserted at the point where the bridge of the nose meets the supraorbital margin (see CD Fig. 15 -4).

Infratrochlear Nerve Block

This involves the following:

Area of Anesthesia

Skin of the medial ends of the eyelids and the side of the root of the nose (see CD Fig. 15-4)

Indications

Repair of lacerations of the medial eyelids and the root of the nose

Procedure

The infratrochlear nerve emerges from the orbital cavity at the junction of the superior and medial walls, which is the site for injection (see CD Fig. 15-4).

External Nasal Nerve Block

This involves the following:

Area of Anesthesia

Skin of the side of the nose down as far as the tip (see CD Fig. 15-4)

Indications

Repair of lacerations of the skin of the nose

Procedure

The external nasal nerve is blocked at the point where it emerges between the nasal bone and the upper lateral nasal cartilage (see CD Fig. 15-4).

Maxillary Nerve Block

This block is not used in emergency medicine. The infraorbital nerve, which is a continuation of the maxillary nerve onto the face, is commonly blocked. Occasionally, the pterygopalatine ganglion is blocked.

Infraorbital Nerve Block

This involves the following:

Area of Anesthesia

Skin of the lower eyelid, the lateral nose, the cheek, and the skin and mucous membrane of the upper lip and the upper gingiva. Since the anesthetic agent also blocks the anterior and middle superior alveolar nerves, the upper incisor, canine, and premolar teeth are also affected (CD Fig. 15-5).

Indications

Lacerations of the cheek, side of the nose, and the upper lip

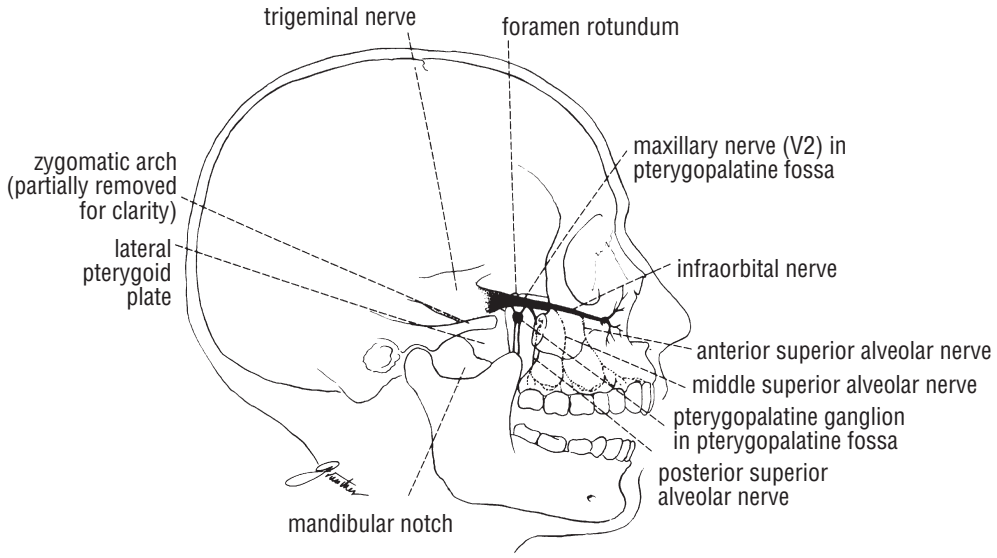

CD Figure 15-5 Lateral view of the skull showing the maxillary (V2) division of the trigeminal nerve leaving the trigeminal ganglion and passing forward to become the infraorbital nerve, which emerges on the face. Note the location of the pterygopalatine ganglion (parasympathetic) in the pterygopalatine fossa. Note also the sensory innervation of the teeth of the upper jaw.

Procedure

The infraorbital nerve emerges from the infraorbital foramen as a direct continuation of the maxillary nerve (CD Fig. 15-6). The opening of the foramen is situated about 1 cm below the midpoint of the lower border of the orbit and faces downward and medially.

Intraoral Method

With the index finger of the left hand palpating the infraorbital foramen through the skin of the cheek and serving as a guide, the needle is inserted into the reflection of the mucous membrane from the upper lip onto the gingiva (see CD Fig. 15-6). The site for the needle insertion is just posterior to the canine tooth and is directed upward to the infraorbital foramen.

Extraoral Method

The infraorbital foramen is palpated below the lower margin of the orbit, and the needle is inserted through the skin and is directed upward and outward toward the foramen (see CD Fig. 15-6).

Pterygopalatine Ganglion Block

The pterygopalatine ganglion is a small parasympathetic ganglion and is suspended from the lower border of the maxillary nerve in the pterygopalatine fossa (CD Fig. 15-7). Passing through the ganglion without interruption are the sensory fibers from the orbit, the nose, the hard and soft palate, the gums, and the tonsillar region of the pharynx.

Area of Anesthesia

The lower nasal cavity, hard and soft palates, the upper gum, the teeth of the upper jaw, and the tonsillar region of the pharynx

Indications

Repair of lacerations involving the palate

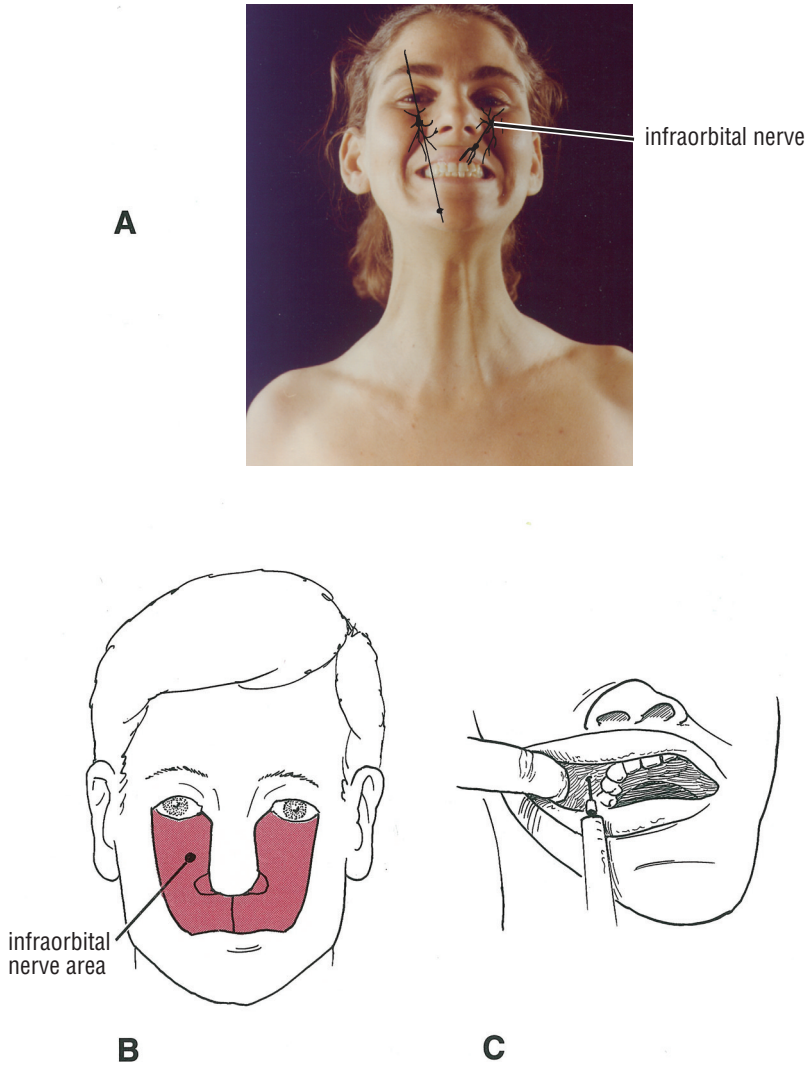

CD Figure 15-6 Infraorbital nerve block. **A.** Extraoral method shows the infraorbital nerve emerging from the infraorbital foramen. The infraorbital foramen lies on the same vertical line that passes through the supraorbital notch, the mental foramen, and the first premolar tooth. The blocking needle is inserted in the direction of the infraorbital foramen just below the lower margin of the orbit. **B.** The area of skin anesthetized by blocking the infraorbital nerve. **C.** Intraoral method. The needle is inserted into the reflection of the mucous membrane from the upper lip onto the gingiva just posterior to the canine tooth and is directed toward the infraorbital foramen.

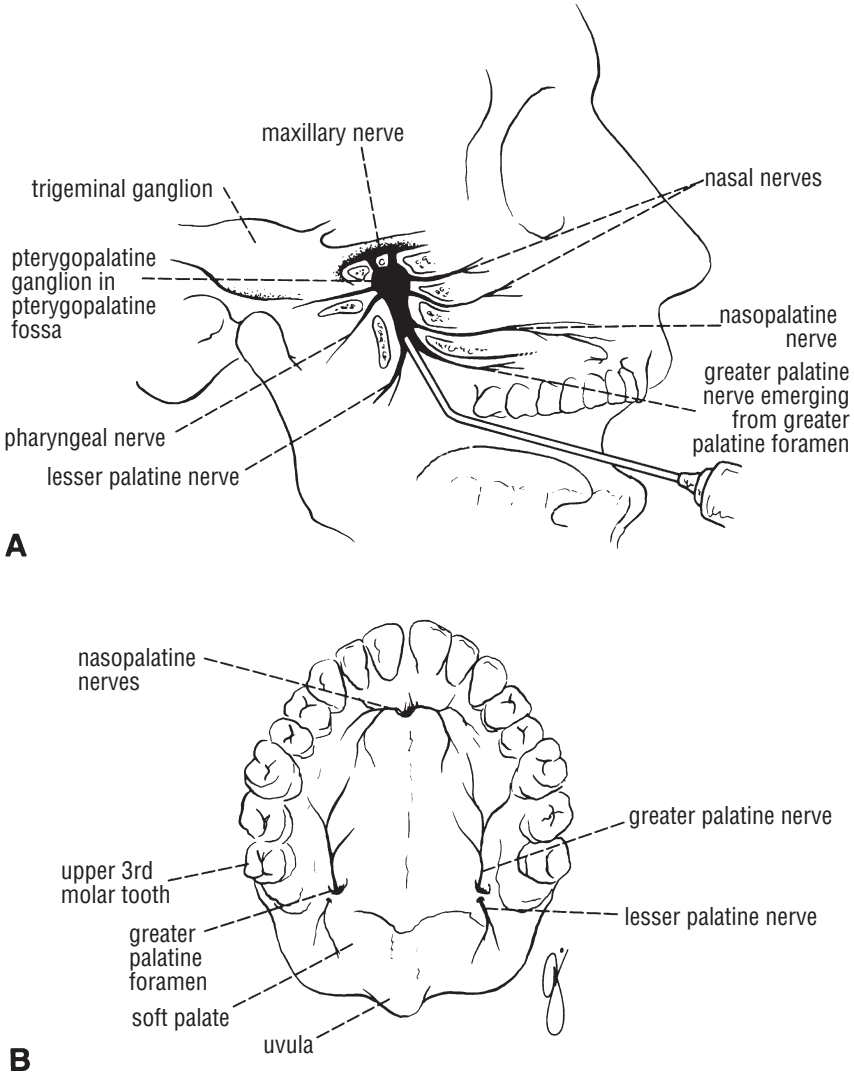

CD Figure 15-7 Blocking the pterygopalatine ganglion. **A.** Lateral view of the skull showing the insertion of the needle into the greater palatine foramen in order to block the ganglion. **B.** The undersurface of the palate showing the position of the greater palatine foramen in relation to the upper third molar tooth and the soft palate. Note the distribution of the branches of the maxillary nerve through the ganglion to the walls of the nose and the palate.

Procedure

The ganglion and, therefore, the sensory fibers may be blocked by inserting a long-angled needle into the greater palatine foramen with the mouth wide open (see CD Fig. 15-7). The foramen is located at the posterior portion of the hard palate just medial to the gumline of the third molar tooth. The greater palatine foramen leads superiorly into the pterygopalatine fossa. Injection of the anesthetic blocks the greater and lesser palatine nerves, the orbital nerves, the nasal nerves, and the pharyngeal nerves.

Mandibular Nerve Block

This block is rarely used. However, the auriculotemporal nerve, the lingual nerve, and the inferior alveolar nerve, which are branches of the mandibular nerve, are commonly blocked.

Auriculotemporal Nerve Block

This involves the following:

Area of Anesthesia

The external auditory meatus, the tympanic membrane, the upper part of the auricle, and the scalp in the temporal region (CD Fig. 15-8)

Indications

Repair of lacerations of the auricle and scalp

Procedure

The auriculotemporal nerve is easily blocked as it ascends in front of the auricle over the posterior root of the zygoma, behind the superficial temporal artery (see CD Fig. 15-8).

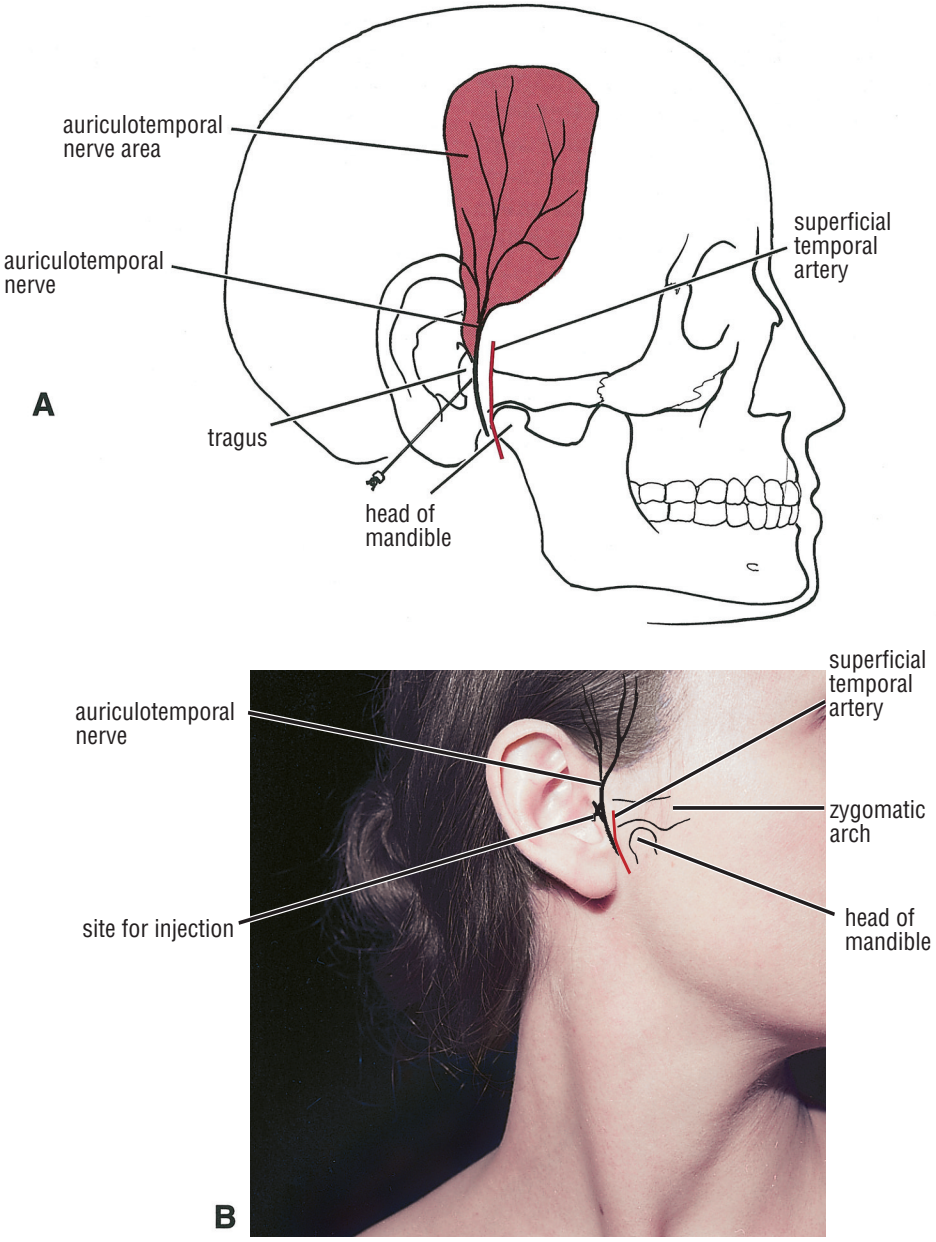

CD Figure 15-8 Blocking the auriculotemporal nerve. **A.** The relationship of the auriculotemporal nerve to the superficial temporal artery and the tragus of the ear. Note the area of skin supplied by this sensory nerve. The needle is inserted just behind the pulsating superficial temporal artery and in front of the tragus; the needle is directed horizontally medially. **B.** The surface marking of the auriculotemporal nerve and its relationship to the superficial temporal artery and the temporomandibular joint. **X** marks the site for injection.

Anatomy of Complications

The superficial temporal artery may be pierced if the needle is inserted too far anteriorly.

Lingual Nerve and Inferior Alveolar Nerve Blocks

These involve the following:

Area of Anesthesia

The lingual nerve supplies the mucous membrane of the anterior two thirds of the tongue and the floor of the mouth (taste is supplied by the chorda tympani branch of the facial nerve), and the lower gums. The inferior alveolar nerve supplies the lower teeth and gums and the skin of the lower lip and chin.

Indications

Repair of lacerations of the tongue, floor of the mouth, and lower lip and chin

Procedure

Both the lingual and inferior alveolar nerves may be blocked as they pass downward and forward in the infratemporal fossa on the lateral surface of the medial pterygoid muscle and on the medial surface of the ramus of the mandible

(CD Fig. 15-9). With the patient's mouth wide open, the anterior border of the ramus of the mandible is palpated just above the third molar tooth. The blocking needle is inserted above the palpating finger and between the mucosa and the inner surface of the ramus of the mandible, and the barrel of the syringe lies in line with the interval between the bicuspids on the opposite side of the mandible (see CD Fig. 15-9). The needle is advanced posteriorly and slightly superiorly until the tip lies in close proximity to the mandibular foramen. The anesthetic solution will infiltrate around the nerves.

Mental Nerve Block

This involves the following:

Area of Anesthesia

The lower lip and gums

Indications

Repair of lacerations of the lower lip

Procedure

The mental nerve may be blocked as it emerges from the mental foramen on the body of the mandible (CD Fig. 15-10). The foramen lies on the same vertical line that passes through the supraorbital notch, the infraorbital foramen, and the first premolar tooth.

Intraoral Method

The left index finger palpates the position of the mental foramen. The needle is inserted through the reflexion of the mucous membrane from the lower lip onto the gum between the apices of the premolar teeth (see CD Fig. 15-10). The point of the needle is directed toward the mental foramen.

A

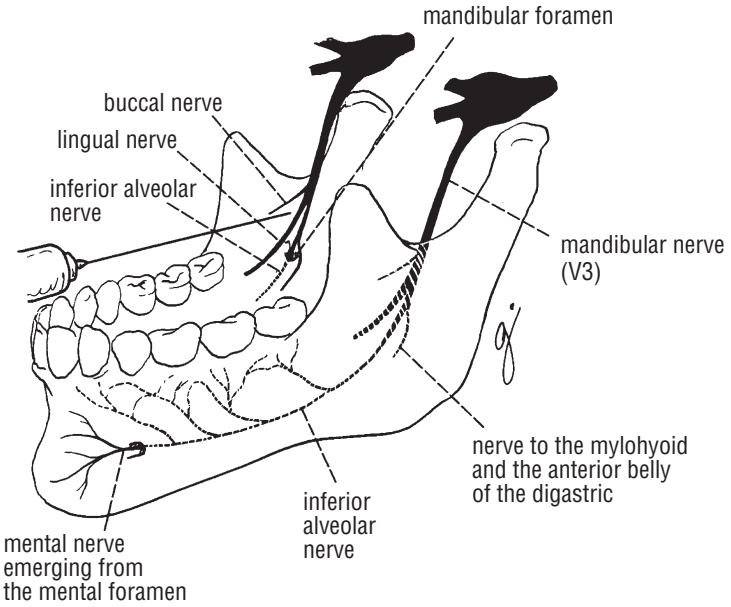

B

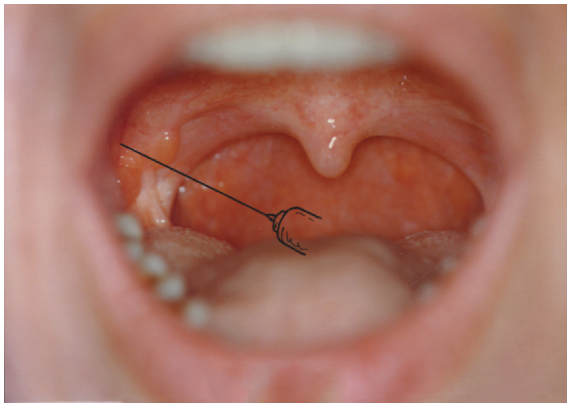

CD Figure 15-9 Lingual and inferior alveolar nerve blocks. **A.** The location of the buccal, lingual, and inferior alveolar nerves in relation to the mandible. **B.** The needle is inserted just above the lower third molar tooth and directed between the mucosa and the inner surface of the ramus of the mandible; the barrel of the syringe lies in line with the interval between the bicuspids on the opposite side of the mandible. The needle is advanced posteriorly and slightly superiorly until the tip lies in close proximity to the mandibular foramen.

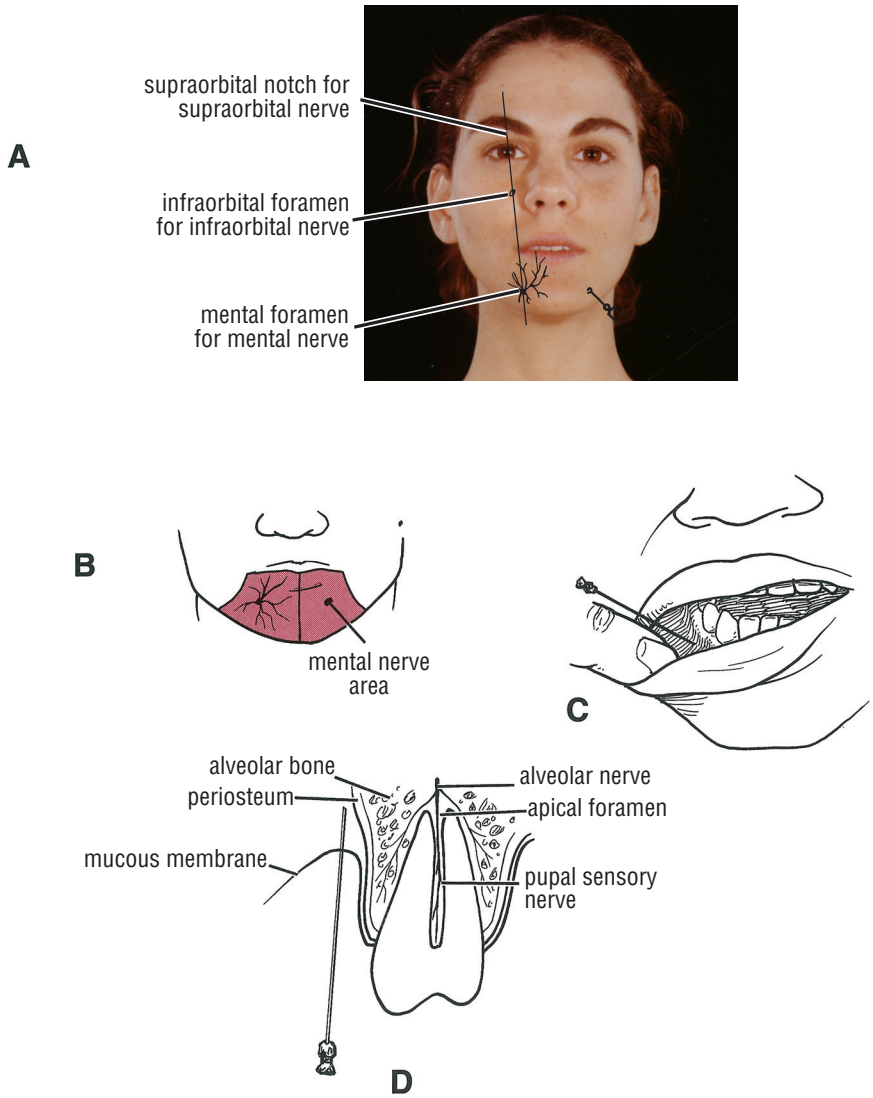

CD Figure 15-10 Mental nerve and tooth nerve blocks. **A.** Extraoral mental nerve block. The surface marking of the mental nerve as it emerges from the mental foramen. The mental foramen lies on the same vertical plane as the supraorbital notch, the pupil (when the patient is looking straight ahead), the infraorbital foramen, and the first premolar tooth. The mental foramen is palpated, and the needle is inserted through the skin and is directed toward the foramen. **B.** Area of skin anesthesia produced by blocking the mental nerve. **C.** Intraoral mental nerve block. The needle is inserted through the reflection of the mucous membrane between the apices of the premolar teeth and is directed toward the mental foramen. **D.** Supraperiosteal infiltration. Needle is inserted through the mucous membrane with the bevel against the periosteum and is advanced until it reaches the level of the apex of the tooth.

Extraoral Method

The mental foramen is palpated, and the needle is inserted through the skin. When the mandible is contacted with the needle, the point is directed toward the mental foramen (see CD Fig. 15-10).

Special Areas for Nerve Blocks

Tooth Nerve Blocks

Two techniques are commonly used—supraperiosteal infiltration and dental nerve blocks.

Supraperiosteal Infiltration

This technique is commonly used in an emergency for the relief of toothache. The anesthetic solution is applied directly to the outer surface of the periosteum opposite the apices of the roots of the teeth (see CD Fig. 15-10). The anesthetic diffuses through the periosteum and the alveolar bone to reach the dental nerve fibers entering the apices of the dental roots; it also reaches the nerves supplying the mucoperiosteum of the gums and the periodontal membrane.

The labiogingival or buccogingival folds, where the mucous membrane lining the lips or cheek are reflected onto the gums, are identified. This may be accomplished in the maxilla by pulling the upper lip downward, and in the case of the mandible by pulling the lower lip upward. At the point where the mucous membrane becomes fused with the periosteum to form the mucoperiosteum of the gum, the needle is inserted with the bevel against the periosteum (see CD Fig. 15-10). The needle is advanced until it reaches the level of the apex of the root of the tooth, and the anesthetic solution is injected. If anesthesia is not produced, it may be necessary to repeat the injection on the palatal surface of the gums. Failure to produce an adequate nerve block may be due to the needle tip being inserted too far away from the

apex of the tooth—that is, too far away from the periosteum or too far above or below the tooth apex. The technique is less successful for mandibular teeth because of the density of the bone structure of the mandible.

The upper teeth are innervated by the anterior, middle, and superior alveolar branches of the maxillary division of the trigeminal nerve. The buccal nerve, a branch of the mandibular division of the trigeminal nerve, supplies the lateral surface of the gum and the greater palatine and the nasopalatine nerves, from the maxillary nerve, supply the medial surface of the gum.

The lower teeth are innervated by the inferior alveolar nerve, a branch of the mandibular division of the trigeminal nerve. The buccal nerve supplies the lateral surface of the gums, and the lingual nerve, a branch of the mandibular nerve, supplies the medial surface.

Dental Nerve Blocks

For the maxillary teeth, the anterior and middle superior alveolar nerves are blocked along with the infraorbital nerve as described on page 232 of the CD. For the mandibular teeth, the inferior alveolar nerve is blocked as described on page 235 of the CD.

Anesthesia of the Nose

This involves the following:

Nasal Interior

The lateral wall of the nose is innervated by the anterior ethmoidal branch of the nasociliary branch of the ophthalmic division of the trigeminal nerve, from branches of the maxillary division of the trigeminal nerve, and from the olfactory nerve. The nasal septum is innervated by branches of the anterior ethmoidal nerve, by branches of the maxillary nerve, and from the olfactory nerve.

Analgesia of the mucous membrane can easily be obtained by placing pledgets soaked in local anesthetic in the nose between the conchae and the septum for 5 to 10 minutes.

Nasal Exterior

The skin of the nose is innervated by the supratrochlear and infratrochlear branches of the ophthalmic division of the trigeminal nerve and the infraorbital nerve, a continuation of the maxillary division of the trigeminal nerve (CD Fig. 15-11). Skin analgesia is obtained by infiltrating first the base of the nose and then the nasofacial groove, thus

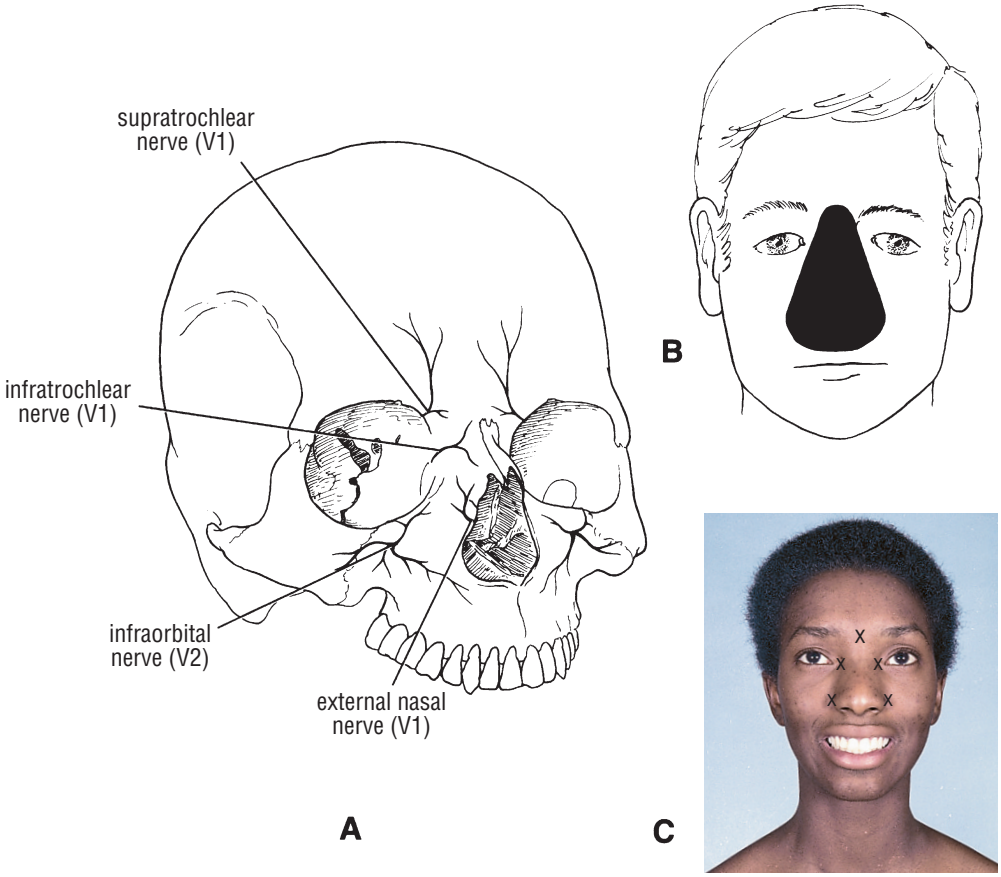

CD Figure 15-11 Anesthesia of the external nose. **A.** The sensory nerves that supply the skin of the nose emerging from the skull. **B.** The extent of the skin supplied by these nerves. **C.** The sites (**X**) where the needle is introduced to produce anesthesia over the area shown in **B.**

A

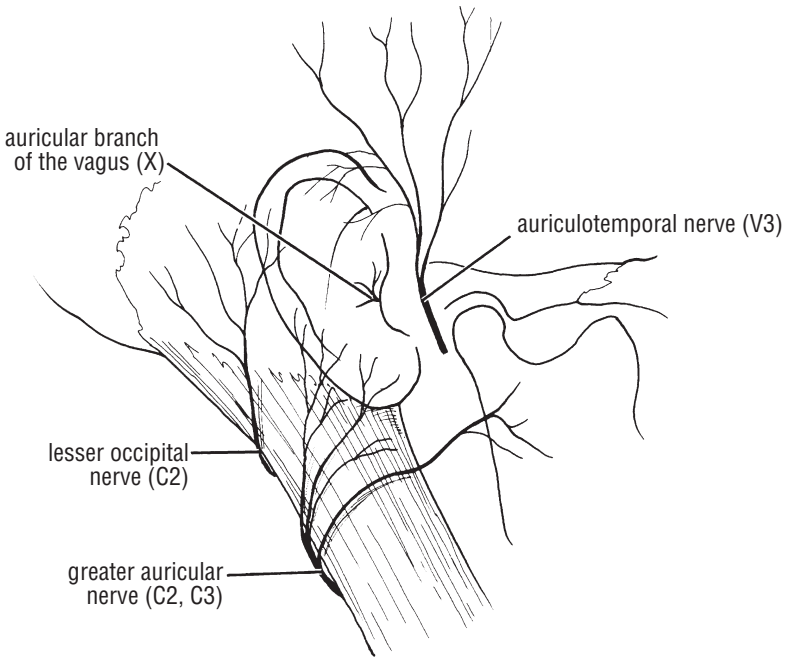

B

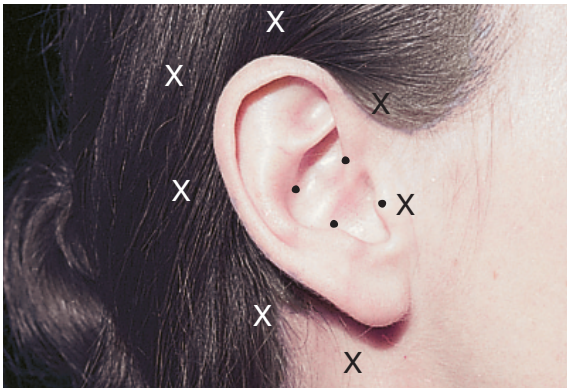

CD Figure 15-12 Ear nerve blocks. **A.** The sensory innervation of the auricle; note the auricular branch of the vagus nerve that supplies part of the external auditory meatus. **B.** The sites (**X**) at which multiple subcutaneous injections may be made circumferentially around the auricle to block the sensory nerves. The external auditory meatus may be anesthetized by using a four-quadrant block (dots).

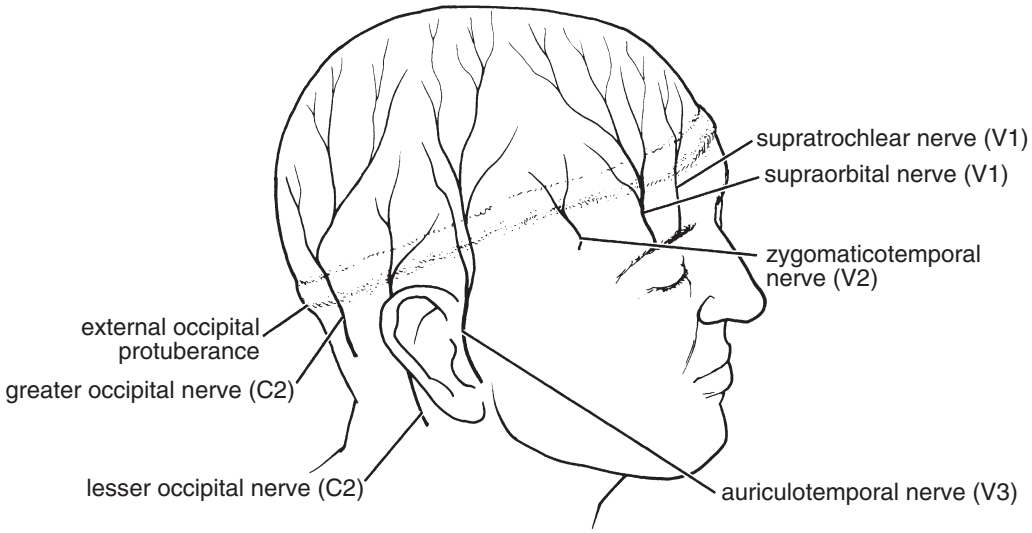

CD Figure 15-13 Scalp nerve block. A subcutaneous infiltration with anesthetic solution is made around the circumference of the head from just above the eyebrows to the region of the external occipital protuberance.

blocking the terminal branches of the ophthalmic and maxillary nerves (see CD Fig. 15-11).

Anesthesia of the Ear

The auricle is innervated by the greater auricular nerve (C2 and C3), a branch of the cervical plexus (CD Fig. 15-12). This nerve mainly supplies the skin on the medial and lateral surfaces of the inferior part of the auricle. The auriculotemporal branch of the mandibular division of the trigeminal nerve supplies the lateral and upper part of the auricle. The lesser occipital nerve (C2) may also supply a small area on the medial surface. The external auditory meatus is also innervated by the auricular branch of the vagus nerve.

Anesthesia of the skin is obtained by multiple subcutaneous injections along a line that is continued circumferentially around the auricle (see CD Fig. 15-12). The external auditory meatus may be anesthetized by using a four-quadrant block of the canal; in addition, several drops of anesthetic solution may be instilled into the canal to anesthetize the tympanic membrane.

Anesthesia of the Scalp

The anterior part of the scalp extending back as far as the vertex is innervated by the supraorbital and supratrochlear branches of the ophthalmic division of the trigeminal nerve (CD Fig. 15-13). The posterior part of the scalp is innervated by the greater occipital nerve (C2) and the lesser occipital nerve (C2). The lateral part of the scalp is supplied by the auriculotemporal branch of the mandibular division of the trigeminal nerve. A small area over the temple is supplied by the zygomaticotemporal nerve from the maxillary division of the trigeminal nerve.

A subcutaneous infiltration with anesthetic solution is made around the circumference of the head from just above the nose and eyebrows to the ear and back to the external occipital protuberance (see CD Fig. 15-13). A large volume of anesthetic is required to completely anesthetize the scalp.

Clinical Problem Solving Questions

Read the following case histories/questions and give the best answer for each.

A 73-year-old woman visited her physician because she had noticed that the right side of her face was sagging downward. She first noticed the condition on waking up two mornings ago. Otherwise she felt very well. On examination the patient had a complete right-sided facial paralysis, the right lower eyelid was drooping, and the right angle of the mouth was sagging. A diagnosis of Bell's palsy was made.

1. Further examination of this patient demonstrated the following signs and symptoms **except** which?
   A. Tears tended to flow easily over the right lower eyelid.
   B. Saliva dribbled from the right corner of her mouth.
   C. The patient was unable to close her right eye completely.
   D. The patient was unable to expose the teeth fully on the right side of her mouth.
   E. The muscles on the right side of her forehead worked perfectly normally when she was asked to raise her right eyebrow.

A 17-year-old boy was seen in the emergency department after receiving a stab wound at the front of the neck. The knife entrance wound was located on the left side of the neck just lateral to the tip of the greater cornu of the hyoid bone. During the physical examination the patient was asked to protrude his tongue, which deviated to the left.

2. The following statements would explain the physical signs in this patient **except** which?
   A. The genioglossus muscles are responsible for protruding the tongue.
   B. The genioglossus muscle is supplied by the glossopharyngeal nerve.
   C. Paralysis of the left genioglossus muscle permitted the right genioglossus to pull the tongue forward and turned the tip to the left side.
   D. The hypoglossal nerve descends in the neck between the internal carotid artery and the internal jugular vein.
   E. At about the level of the tip of the greater cornu of the hyoid bone the hypoglossal nerve turns forward and crosses the internal and external carotid arteries and the lingual artery to enter the tongue.
   F. The point of the knife blade severed the left hypoglossal nerve.

A 43-year-old woman was seen in the emergency department with a large abscess in the middle of the right posterior triangle of the neck. The abscess was red, hot, and fluctuant. The abscess showed evidence that it was pointing and about to rupture. The physician decided to incise the abscess and

insert a drain. The patient returned to the department for the dressings to be changed 5 days later. She stated that she felt much better and that her neck was no longer painful. However, there was one thing that she could not understand. She could no longer raise her right hand above her head to brush her hair.

3. The following statements explain the signs and symptoms in this case, suggesting that the spinal part of the accessory nerve had been incised, **except** which?
   A. To raise the hand above the head, it is necessary for the trapezius muscle, assisted by the serratus anterior, to contract and rotate the scapula so that the glenoid cavity faces upward.
   B. The trapezius muscle is innervated by the spinal part of the accessory nerve.
   C. As the spinal part of the accessory nerve crosses the posterior triangle of the neck, it is deeply placed, being covered by the skin, the superficial fascia, the investing layer of deep cervical fascia, and the levator scapulae muscle.
   D. The surface marking of the spinal part of the accessory nerve is as follows: Bisect at right angles a line joining the angle of the jaw to the tip of the mastoid process. Continue the second line downward and backward across the posterior triangle.
   E. The knife opening the abscess had cut the accessory nerve.

A 35-year-old woman had a partial thyroidectomy for the treatment of thyrotoxicosis. During the operation a ligature slipped off the right superior thyroid artery. To stop the hemorrhage, the surgeon blindly grabbed for the artery with artery forceps. The operation was completed without further incident. The following morning the patient spoke with a husky voice.

4. The following statements about this patient would explain the husky voice **except** which?
   A. Laryngoscopic examination revealed that the right vocal cord was slack, causing the huskiness of the voice.
   B. The vocal cord is tensed by the contraction of the cricothyroid muscle.
   C. The cricothyroid muscle tilts back the cricoid cartilage and pulls forward the thyroid cartilage.
   D. The cricothyroid muscle is innervated by the recurrent laryngeal nerve.
   E. The superior thyroid artery is closely related to the external laryngeal nerve.

A 43-year-old woman visited her physician complaining of severe intermittent pain on the right side of her face. The pain was precipitated by exposing the right side of her face to a draft of cold air. The pain was stabbing in nature and lasted about 12 hours before finally disappearing. When asked to point out on her face the area where the pain was experienced, the patient mapped out the skin area over the right side of the lower jaw extending backward and upward over the side of the head to the vertex.

5. The following signs and symptoms in this patient strongly suggest a diagnosis of trigeminal neuralgia **except** which?
   A. The skin area where the patient experienced the pain was innervated by the mandibular division of the trigeminal nerve.
   B. The stabbing nature of the pain is characteristic of the disease.
   C. The trigger mechanism, stimulation of an area that received its sensory innervation from the trigeminal nerve, is characteristic of trigeminal neuralgia.
   D. Examination of the actions of the masseter and the temporalis muscles showed evidence of weakness on the right side.
   E. The patient experienced hyperesthesia in the distribution of the right auriculotemporal nerve.

A 10-year-old boy was playing darts with his friends. He bent down to pick up a fallen dart when another dart fell from the dart board and hit him on the side of his face. On examination in the emergency department a small skin wound was found over the right parotid salivary gland. Then, 6 months later, the boy's mother noticed that before mealtimes the boy began to sweat profusely on the facial skin close to the healed dart wound.

6. The following statements can explain this phenomenon **except** which?
   A. The point of the dart had entered the parotid salivary gland and damaged the parasympathetic secretomotor fibers to the gland.
   B. The secretomotor fibers to the parotid gland arise in the otic ganglion.
   C. The preganglionic parasympathetic fibers originate in the superior salivatory nucleus of the facial nerve.
   D. The skin over the parotid salivary gland is innervated by the great auricular nerve, which was also damaged by the dart.
   E. On regeneration of the damaged nerves some of the parasympathetic nerves to the parotid salivary gland had crossed over and joined the sympathetic secretomotor nerves to the sweat glands in the distal end of the great auricular nerve.
   F. The patient has Frey's syndrome.

   A 31-year-old woman fell off her bicycle and lacerated the skin of her forehead just above the left eyebrow.

7. What is the sensory innervation of the skin of the forehead? Where may these nerves be blocked?

   A 27-year-old man was involved in a motorcycle accident and was seen in the emergency department with

extensive lacerations of the right ear. It was decided to suture the skin lesions under local anesthesia.

8. How would you anesthetize the ear?

A 63-year-old woman visited her physician with a swelling over the parotid gland on the right side. She stated that she had first noticed the swelling 3 months previously, and since that time it had rapidly increased in size. Recently, she had noticed that the right side of her face "felt weak" and she could no longer whistle for her dog. On examination, a hard swelling deeply attached to the parotid gland was found. On testing the facial muscles, it was found that the muscles on the right side were weaker than those on the left side.

9. What is the connection between the parotid swelling and the right-sided facial weakness?

10. On examination, a patient is found to have a bitemporal hemianopia. An enlargement of which anatomic structure is likely to cause this condition?

11. A patient is suspected of having a lesion of the glossopharyngeal nerve. How would you test the integrity of this cranial nerve?

12. A 47-year-old woman is seen by a neurologist because of trouble reading the newspaper. She said that the print starts to tilt and she begins to see double. She also stated that she has difficulty walking down steps because she cannot easily look downward with her right eye. On physical examination, the patient was found to have weakness of the movement of the right eye, both downward and laterally. Using your knowledge of anatomy, explain the signs and symptoms.

Answers and Explanations

1. **E** is the correct answer. In this patient all the facial muscles on the right side were paralyzed. When making the diagnosis of Bell's palsy, it is imperative that one makes the distinction between an upper motor neuron palsy and a lower motor neuron palsy. The part of the facial nucleus of the facial nerve that controls the muscles of the upper part of the face receives corticonuclear fibers from both cerebral hemispheres. Therefore, it follows that with a lesion involving the upper motor neurons, only the muscles of the lower part of the face will be paralyzed. In this patient all the facial muscles on the affected side were paralyzed, indicating that the lesion was confined to the facial nerve.

2. **B** is the correct answer. The genioglossus muscle is supplied by the hypoglossal nerve.

3. **C** is the correct answer. The spinal part of the accessory nerve lies superficial to the levator scapulae muscle in the posterior triangle of the neck.

4. **D** is the correct answer. The cricothyroid muscle is innervated by the external laryngeal nerve, which was damaged in this patient.

5. **D** is the correct answer. The motor portion of the trigeminal nerve is unaffected in patients with trigeminal neuralgia.

6. **C** is the correct answer. The secretomotor fibers to the parotid salivary gland originate in the inferior salivatory nucleus of the glossopharyngeal nerve.

7. The skin of the forehead is innervated by the supraorbital and supratrochlear branches of the frontal nerve, a branch of the ophthalmic division of the trigeminal nerve. The nerves may be blocked as they emerge onto the forehead around the superior margin of the orbital cavity.

8. The auricle receives its sensory innervation from the greater auricular nerve (C2 and C3), the auriculotemporal nerve (mandibular division of the trigeminal nerve), and the auricular branch of the vagus nerve. Analgesia of the skin can be obtained by multiple subcutaneous injections that are continued circumferentially around the auricle.

9. The facial nerve, the retromandibular vein, and the external carotid artery lie within the parotid salivary gland. This patient had a highly invasive carcinoma of the right parotid gland, which quickly involved the right facial nerve, with consequent weakness of the right facial muscles. The method used clinically to test the integrity of the facial nerve is fully described on CD p. 228. A benign tumor of the parotid gland tends not to damage the facial nerve.

10. Bitemporal hemianopia is a loss of both temporal fields of vision and is due to the interruption of the optic nerve fibers derived from the medial halves of both retinae. Pressure on the optic chiasma by a tumor of the pituitary gland is the most common cause of the condition.

11. The glossopharyngeal nerve supplies the mucous membrane of the posterior third of the tongue with taste fibers and those for common sensation. These sensations can easily be tested by using appropriate stimuli.

12. The difficulty with reading and the diplopia can be explained by paralysis of the right superior oblique muscle. When a patient with paralysis of the superior oblique muscle looks straight downward, the affected eye turns medially as well as downward. Moreover, the patient has great difficulty turning that eye downward and laterally. This abnormality can be explained as follows: Contraction of the inferior rectus muscle rotates the eyeball so that the cornea is depressed downward. Because of the manner of its insertion, the inferior rectus muscle also rotates the eyeball medially. This tendency to rotate the eyeball medially is normally neutralized by simultaneous contraction of the superior oblique muscle, whose action is to rotate the eyeball laterally as well as to depress the cornea downward.